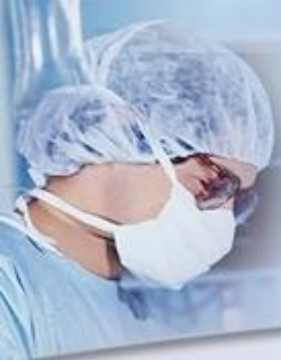



Vestibularis schwannom

- symptomer, diagnosticering og behandling

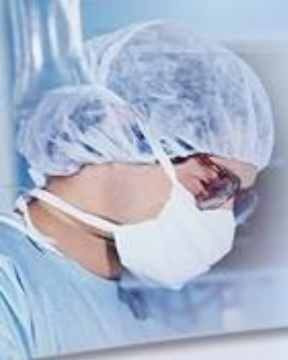*Per Cayé-Thomasen
Øre-næse-hals-kirurgisk klinik, Rigshospitalet
per.caye-thomasen.01@regionh.dk*



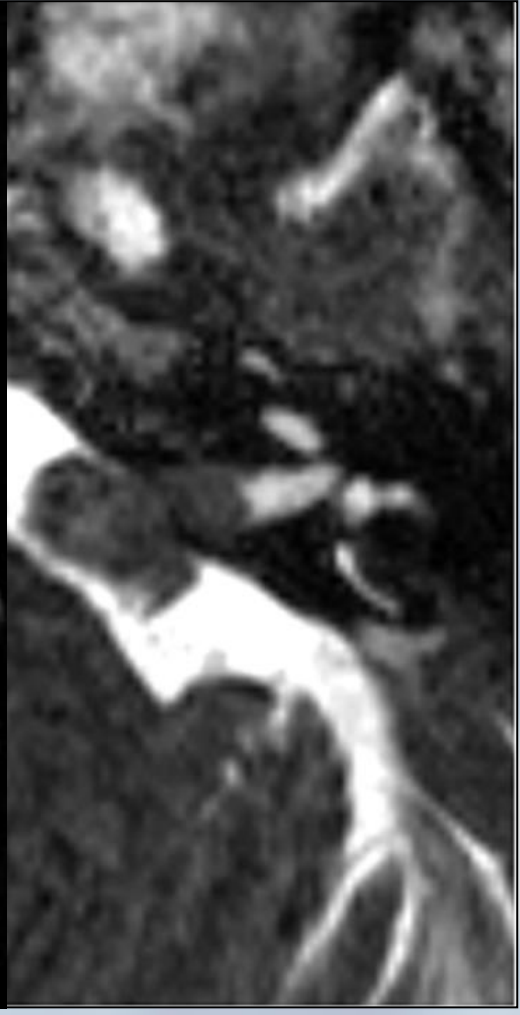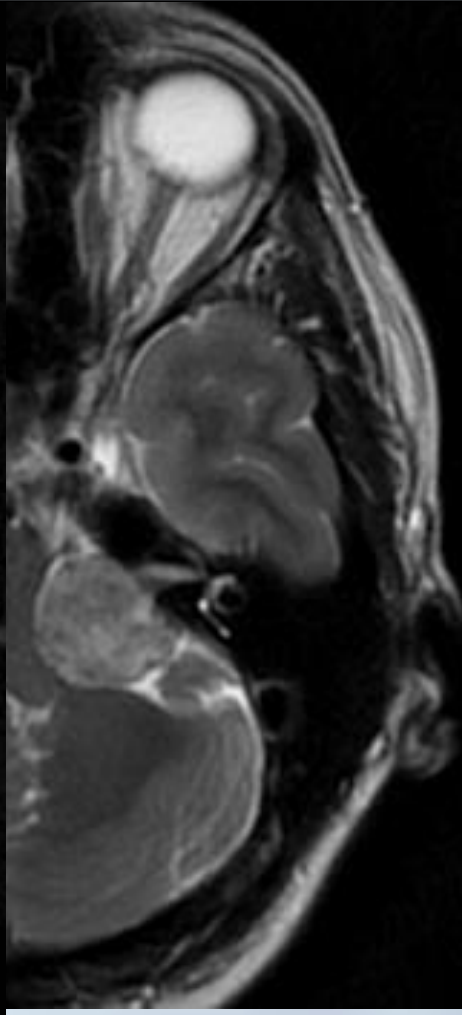
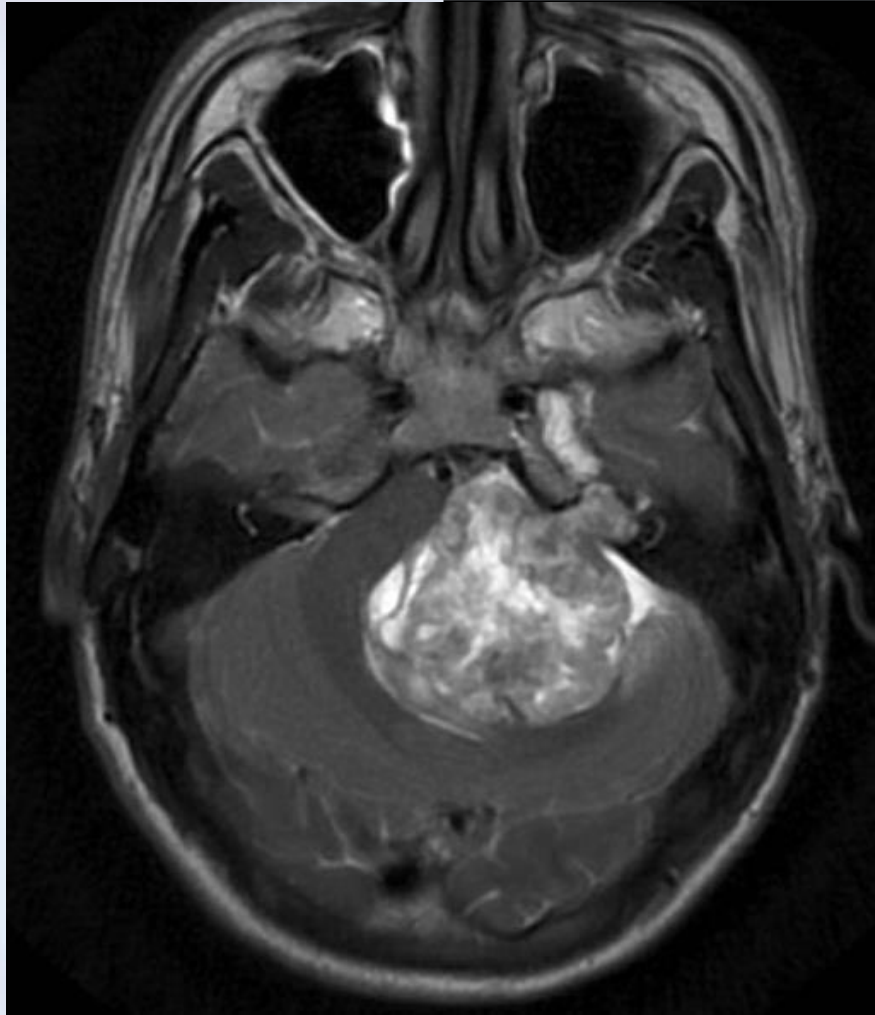
Tumorer i cerebello-pontine vinkel

10% af intrakranielle tumorer involverer cerebello-pontine vinkel

| | |
|--------------------------|--|
| Vestibularis schwannomer | ~80% |
| Meningiomer | ~10% |
| Epidermoidcyster | ~ 5% |
| Andre tumorer | ~ 5% (f.eks. arachnoidalcyste, facialis schwannom) |



Vestibularis schwannom





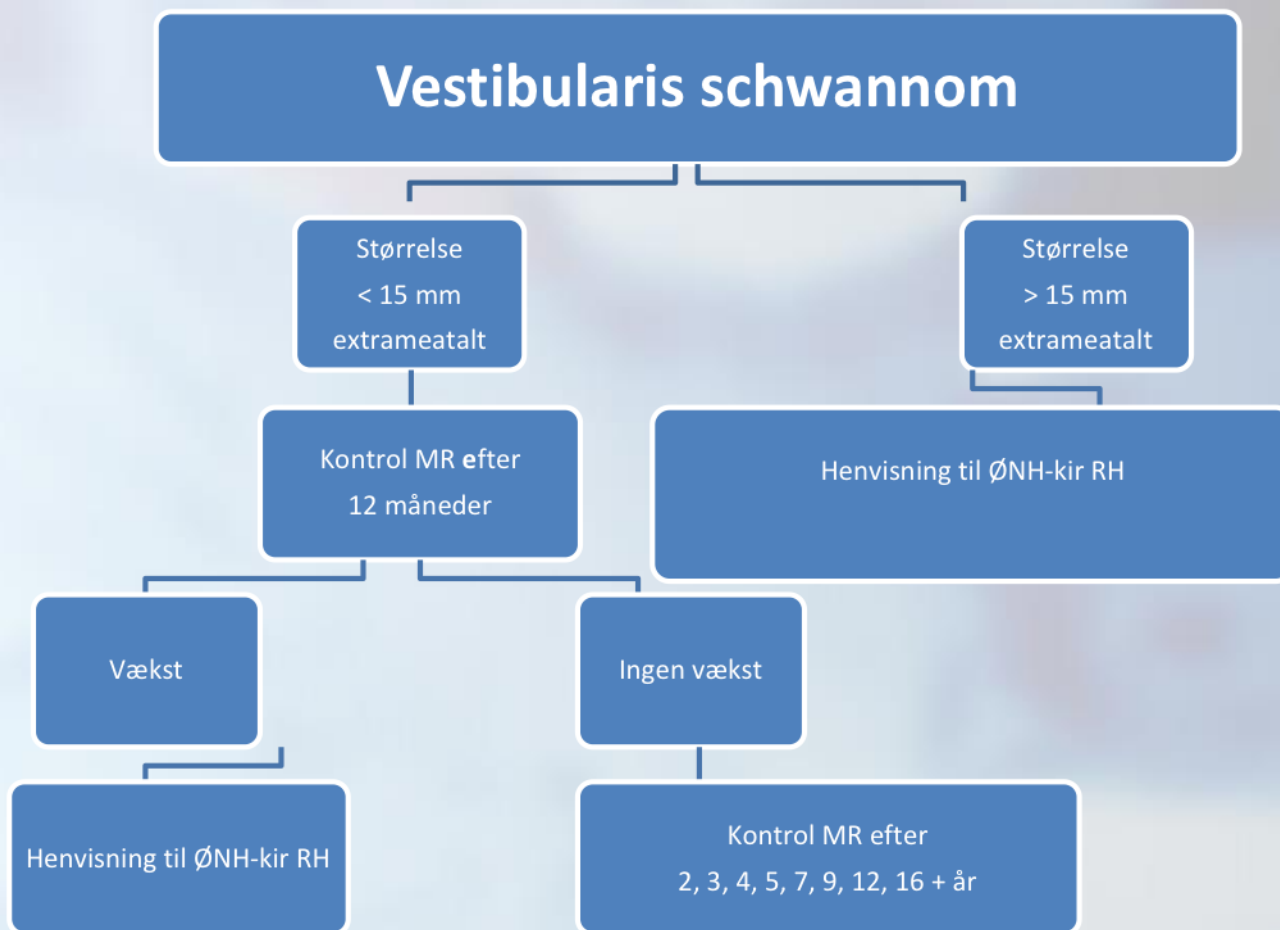
Vestibularis schwannom

Efter diagnose henvises følgende patienter til ØNH-kir. afd., Rigshospitalet:

- 1. Patienter med en tumor større end 15mm extrameatalt ved diagnosen**
(den intrameatale del af tumor skal ikke inkluderes i opmålingen)
- 2. Alle patienter med tumorvækst**
- 3. Patienter med ønske om hørebevarende kirurgi** (DS>50%, PTA<50dB)
- 4. Patienter med andre problemstillinger der kan indikere kirurgi eller bestråling**
(f.eks. utålelig svimmelhed/balanceusikkerhed der ikke svinder ved vestibulær træning, ønske om aktiv behandling, eller andet)



Vestibularis schwannom





Vestibularis schwannom

Efter henvisning bliver patienterne allokeret til enten

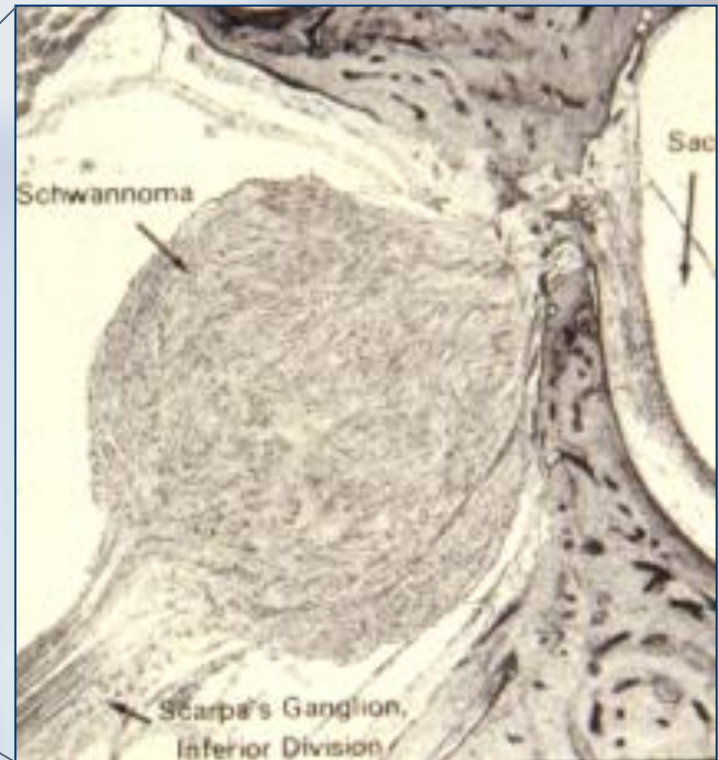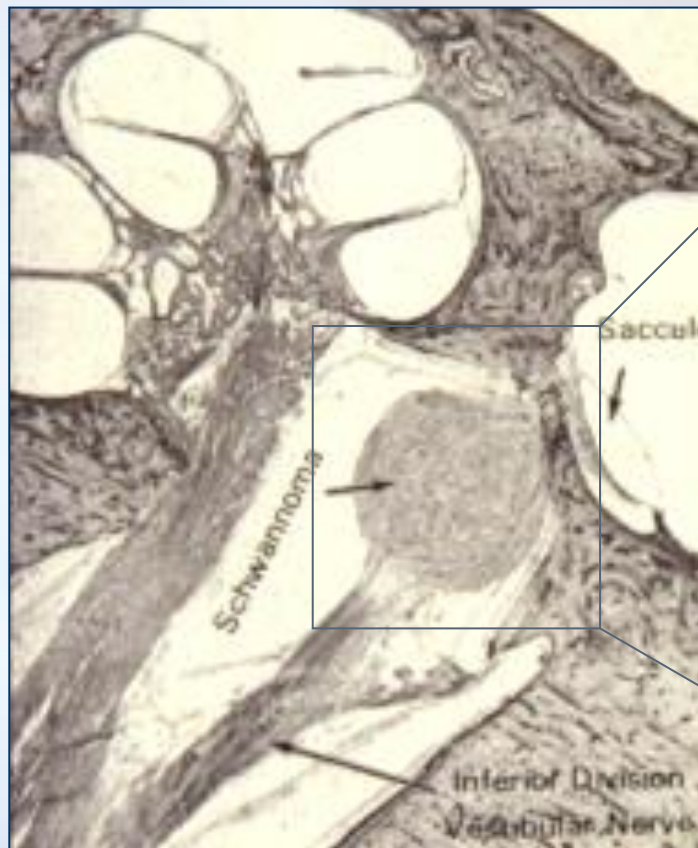- **observation** (lokal audiologisk afd.)
- **strålebehandling** (neuro-onkologisk, RH)
- **operation** (ØNH/RH eller neurokir./RH)



Vestibularis schwannom

Terminologi

Akustikus neurinom = vestibularis schwannom

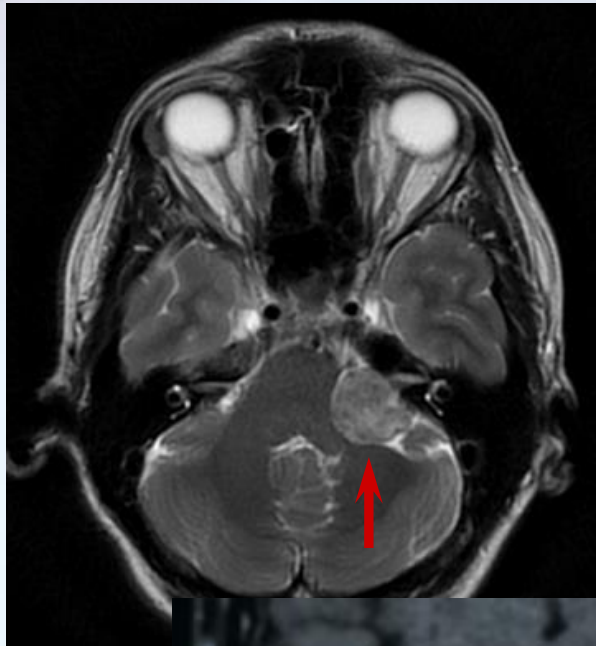




Vestibularis schwannom

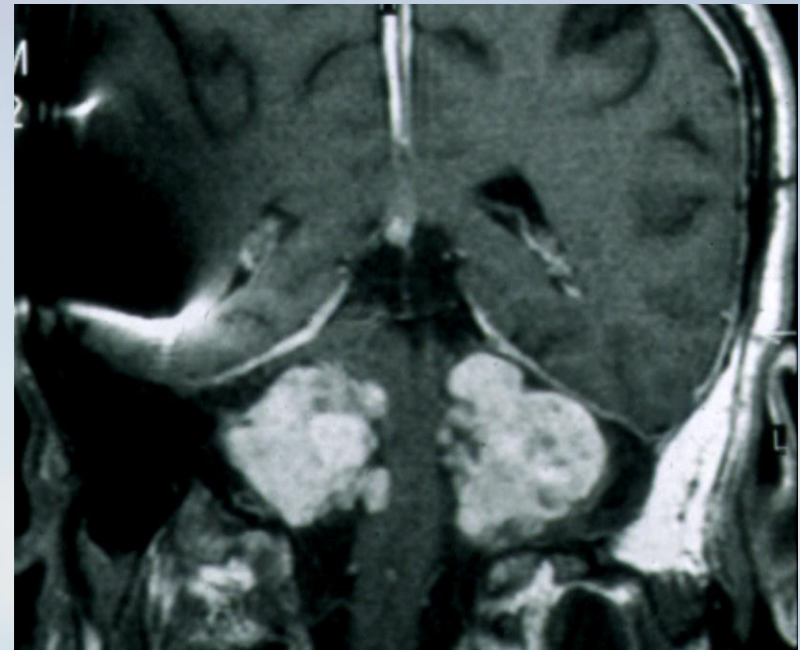
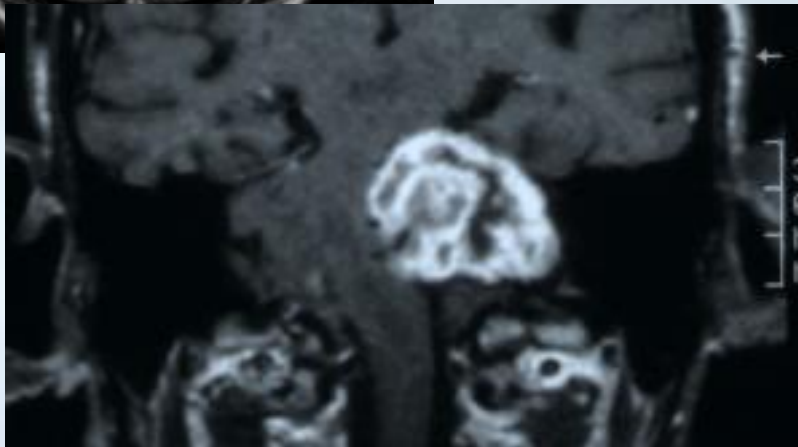
Klassifikation

Sporadisk vestibularis schwannom (unilateral)



NF2-associeret vestibularis schwannom (bilateral)

Cystisk variant





Vestibularis schwannom

Symptomer

Høretab $>90\%$

Tinnitus $\sim 80\%$

Svimmelhed / balanceusikkerhed $\sim 80\%$

Trigeminuspåvirkning (ændret ansigtssensibilitet) $\sim 30\%$

Facialispåvirkning $<5\%$

Cerebellare symptomer (ataksi, dysdiadokokinese)

Tegn på truende incarceration (kvalme, opkast, bevidsthedspåv.)



Vestibularis schwannom

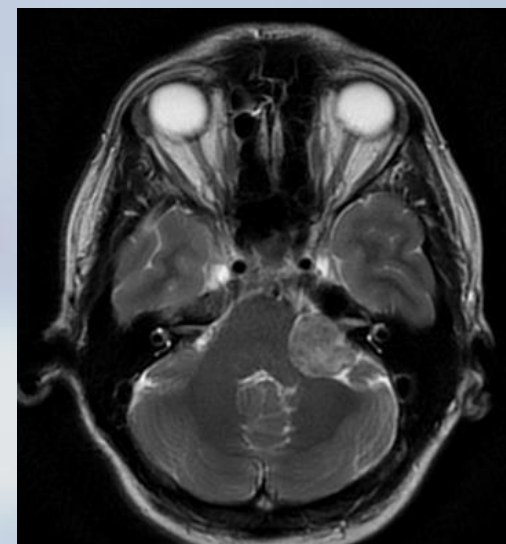
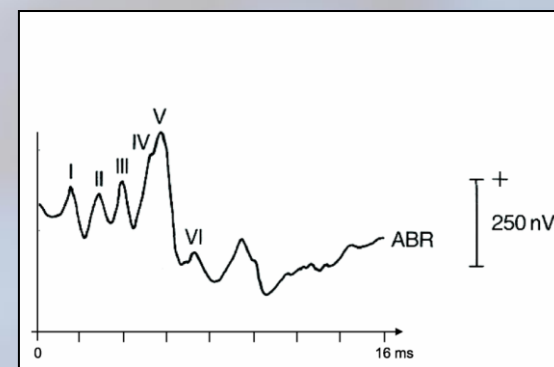
Diagnose

Ved unilateralt høretab eller tinnitus:

- hjernestammeaudiometri
- eller MR

Ved andre neurologiske symptomer:

- MR

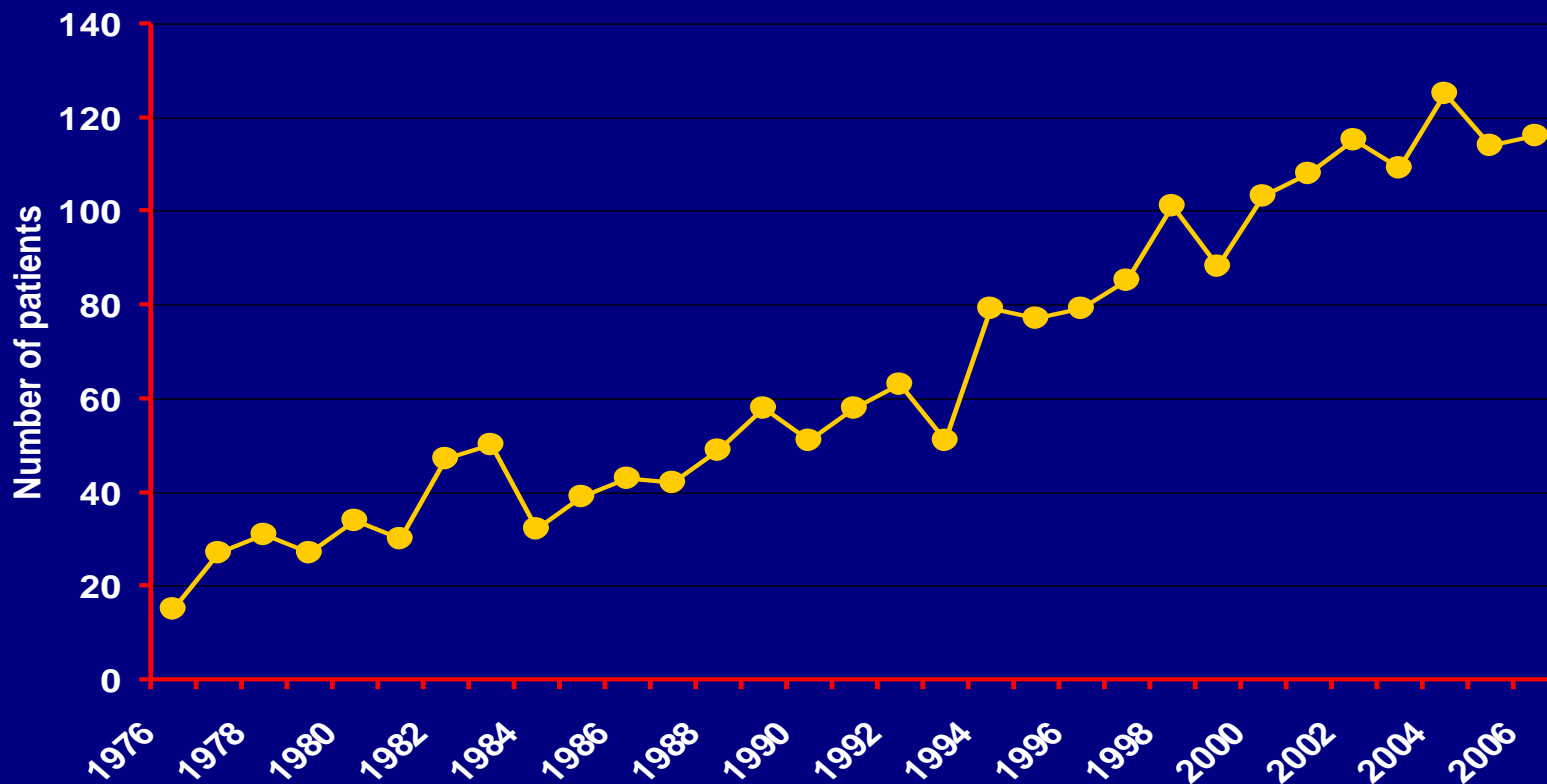




Vestibularis schwannom

Epidemiologi

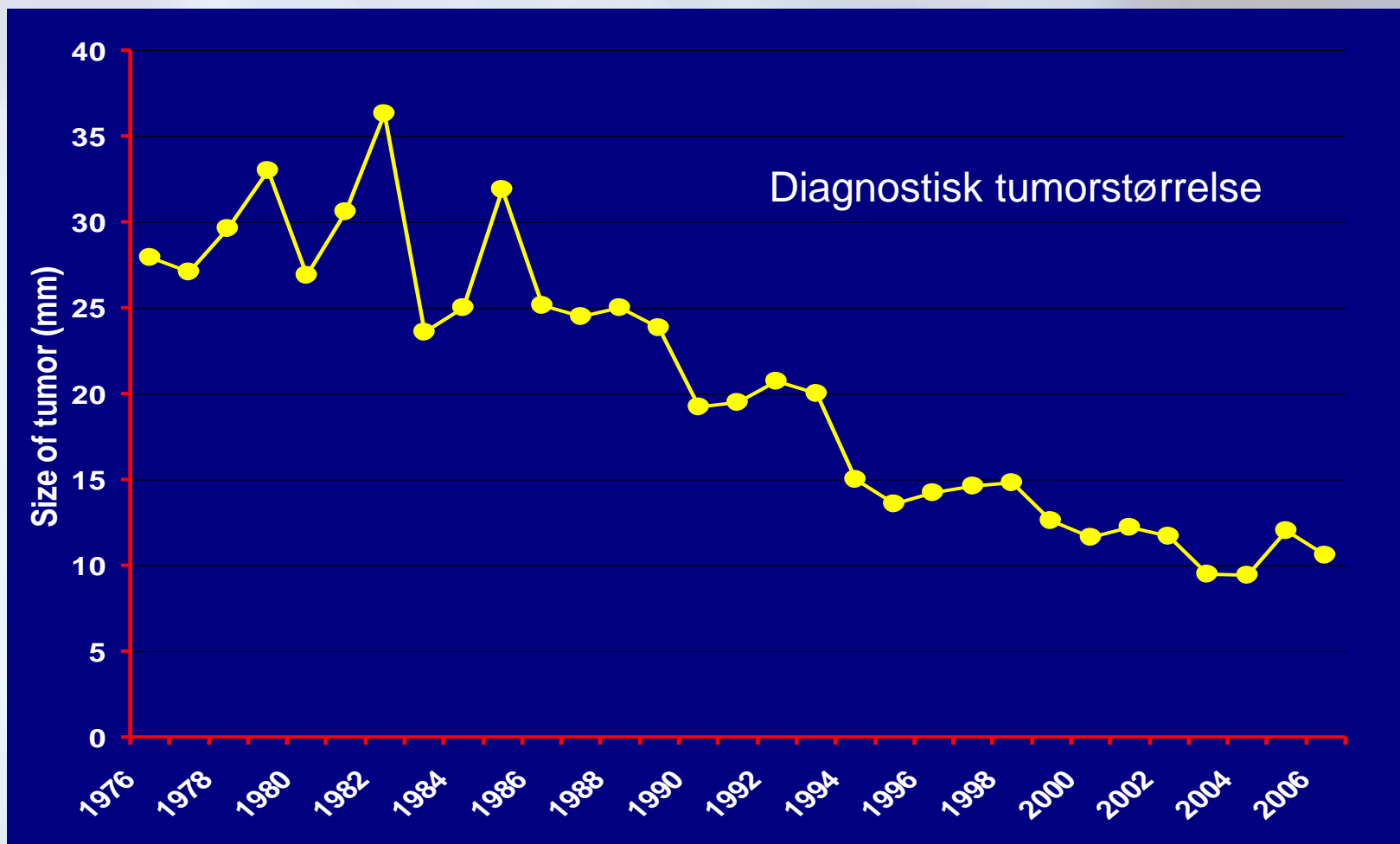
Incidens af vestibularis schwannomer i Danmark





Vestibularis schwannom

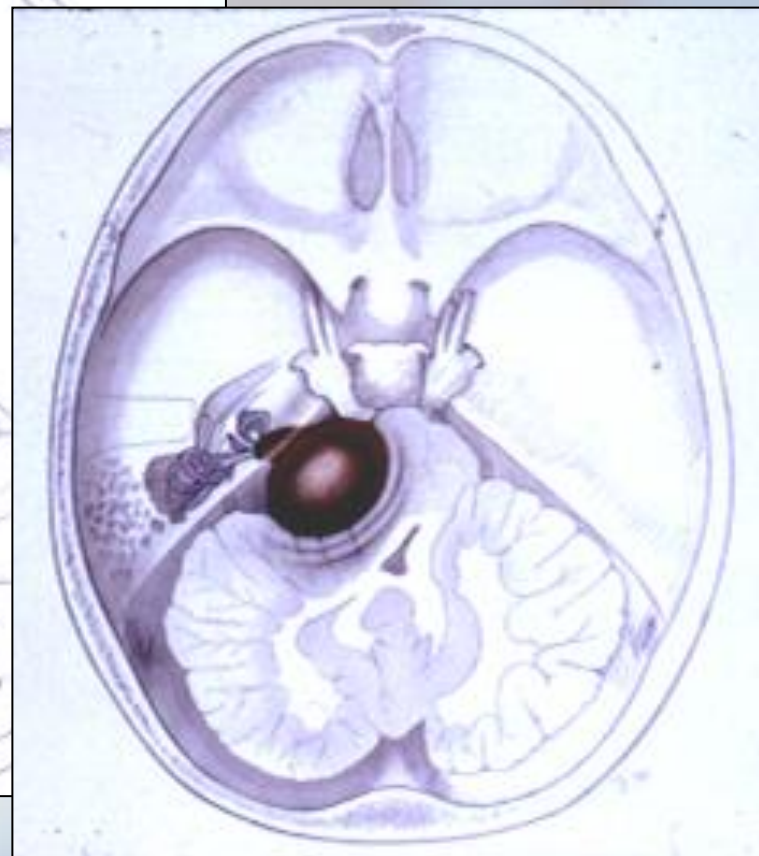
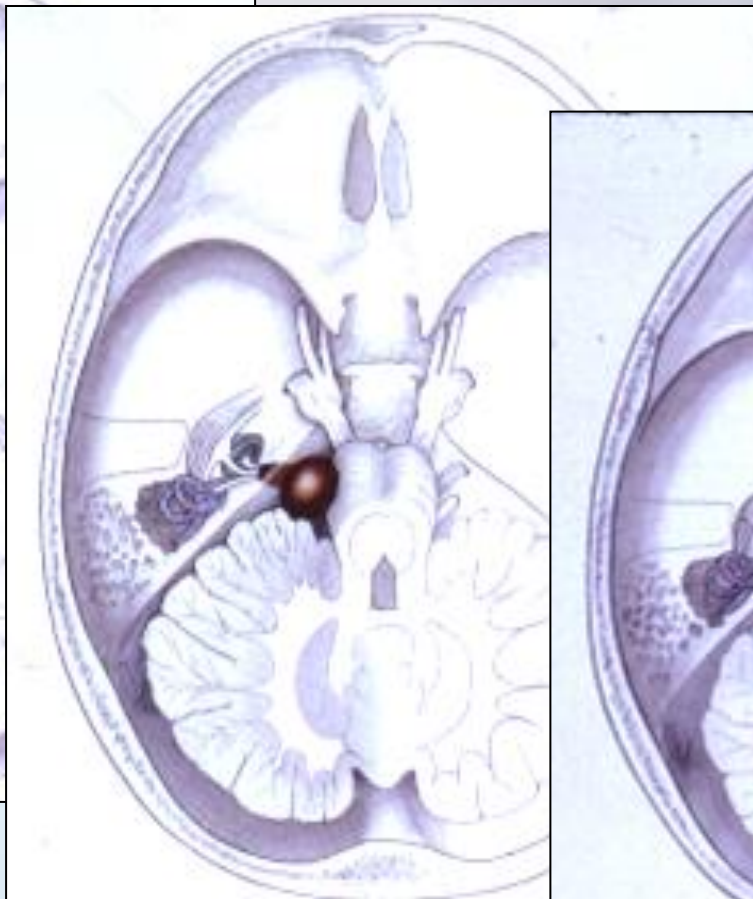
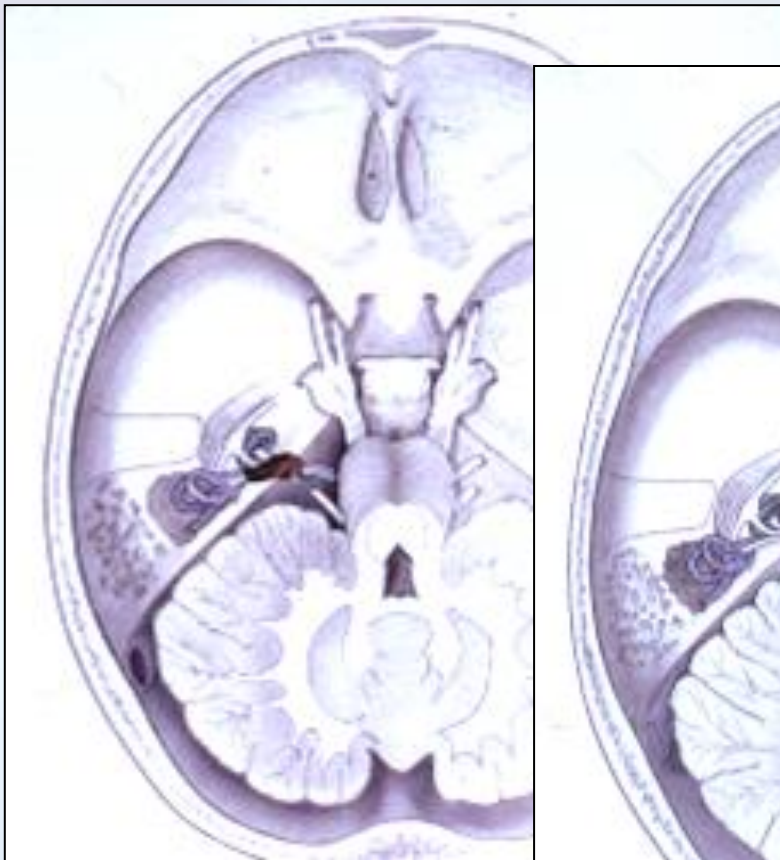
Epidemiologi





Vestibularis schwannom

Naturhistorie

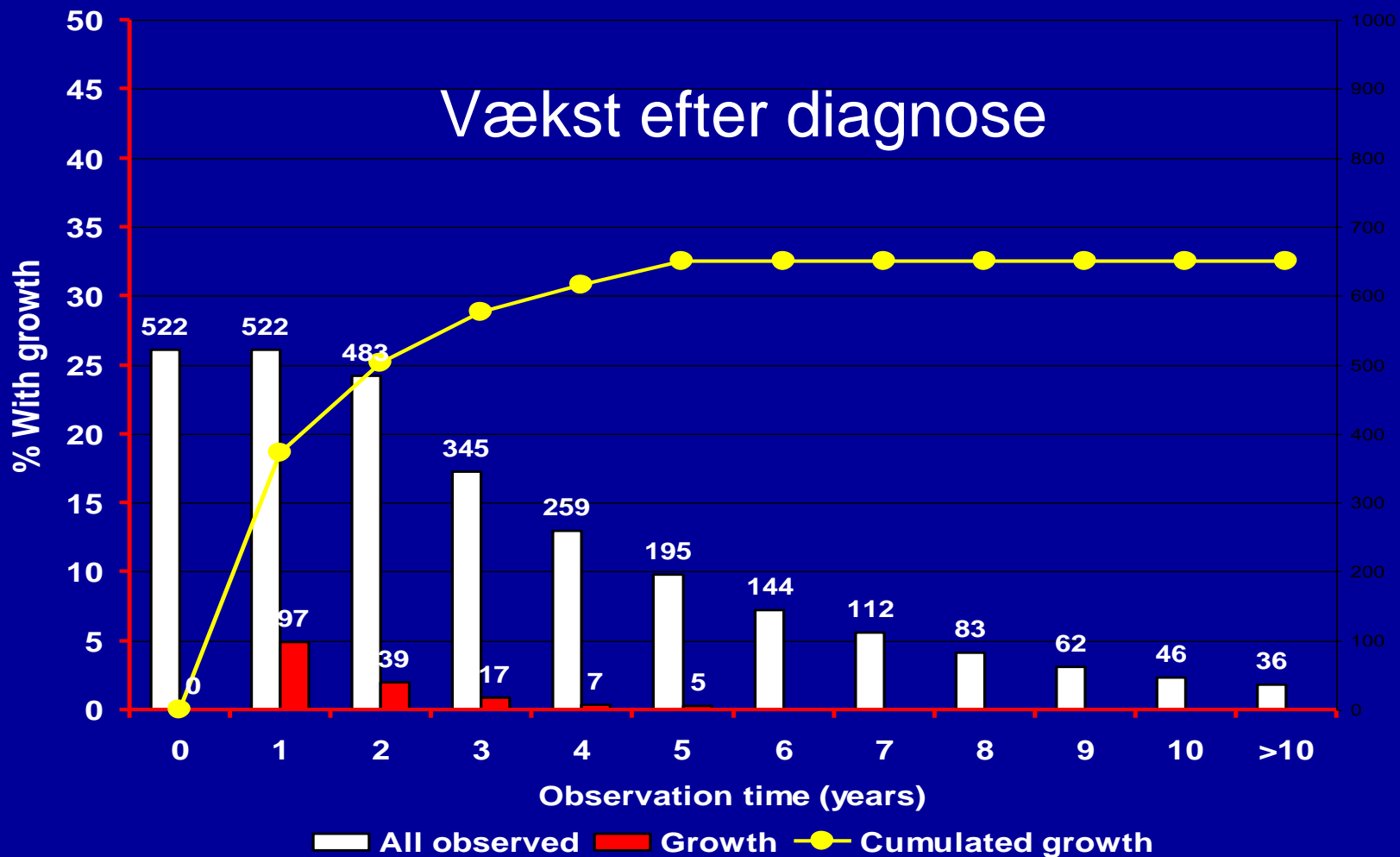




Vestibularis schwannom

Naturhistorie

Vækst efter diagnose

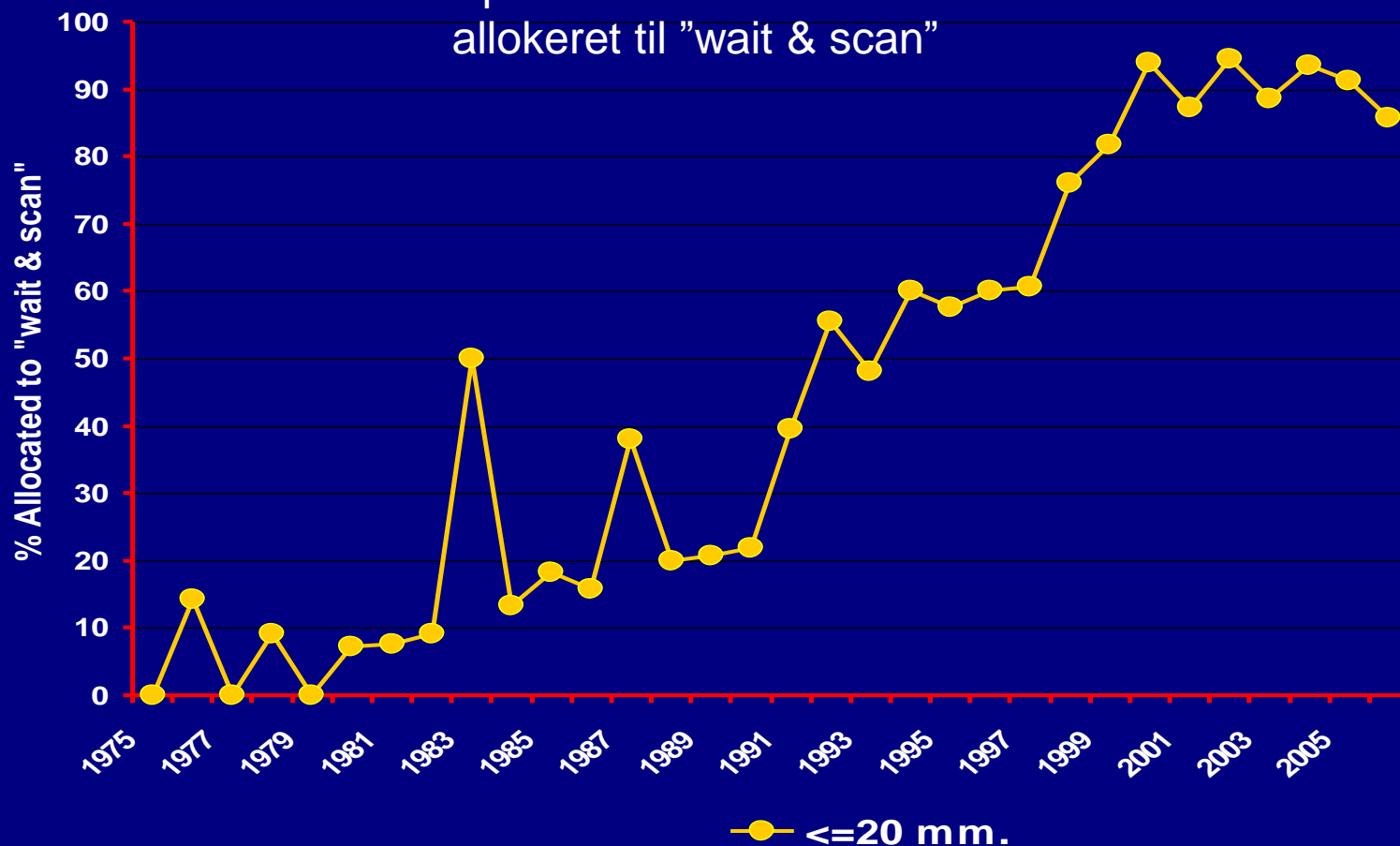



Vestibularis schwannom

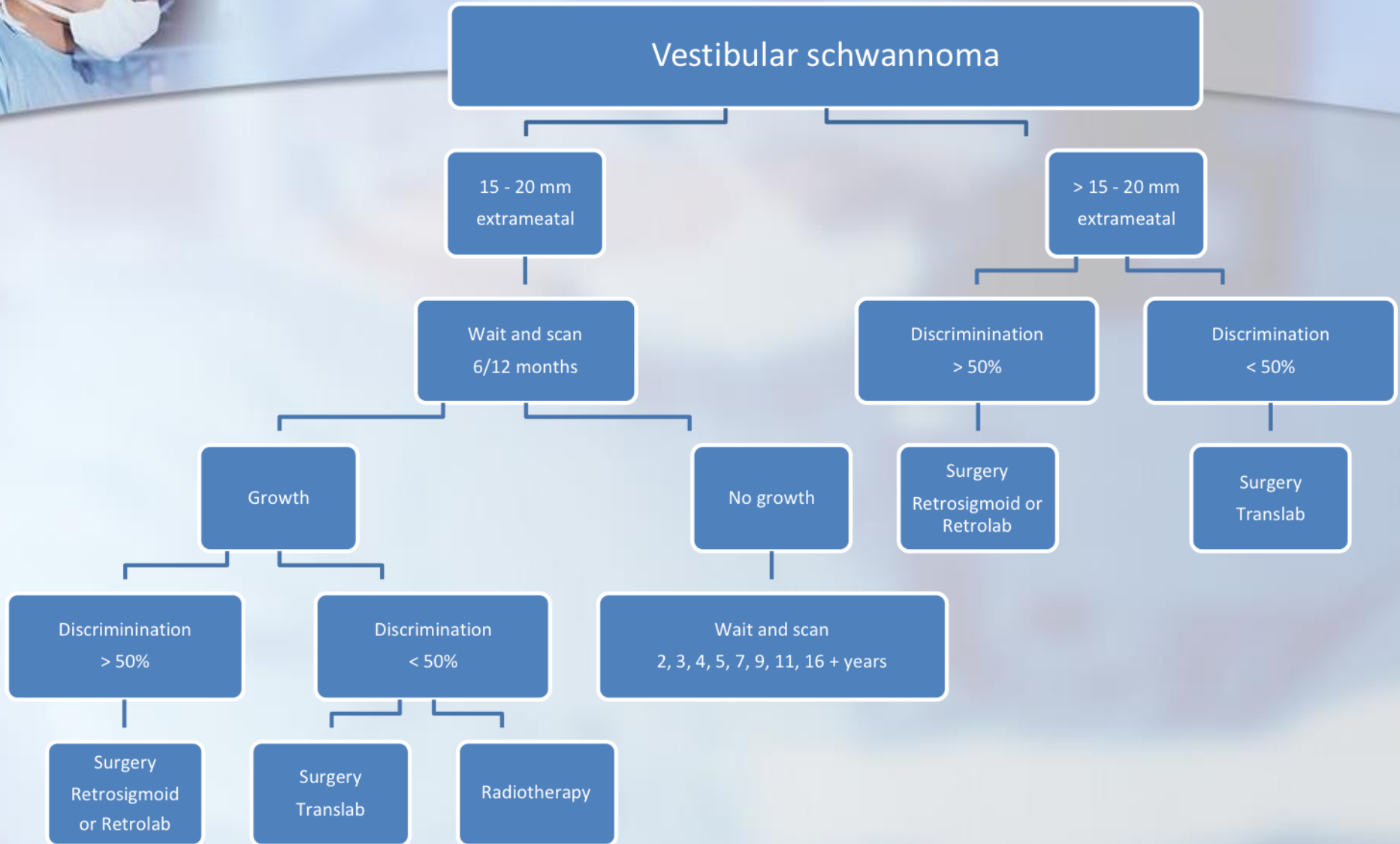
Naturhistorie

Andel af patienter med tumor ≤ 20 mm
allokeret til "wait & scan"

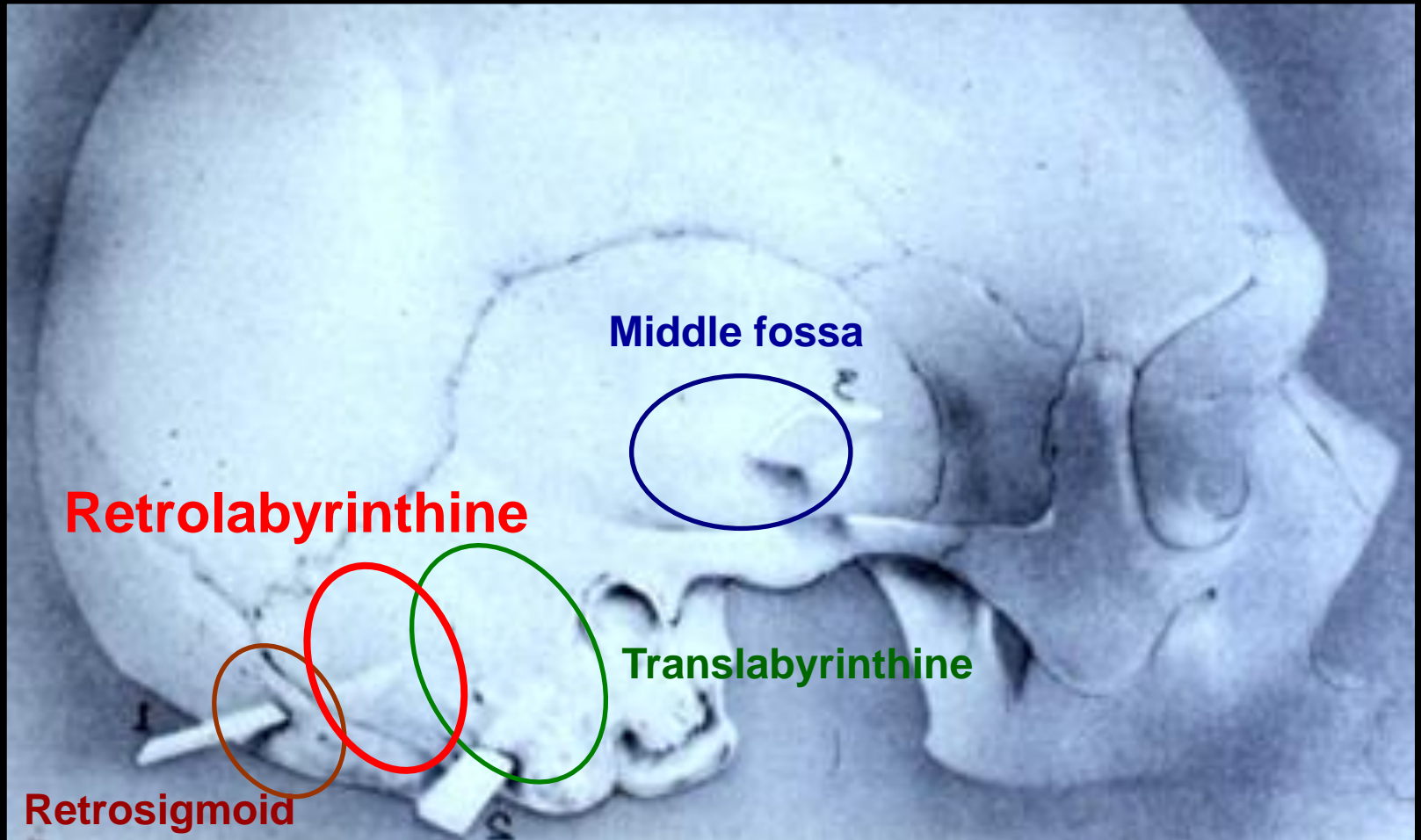


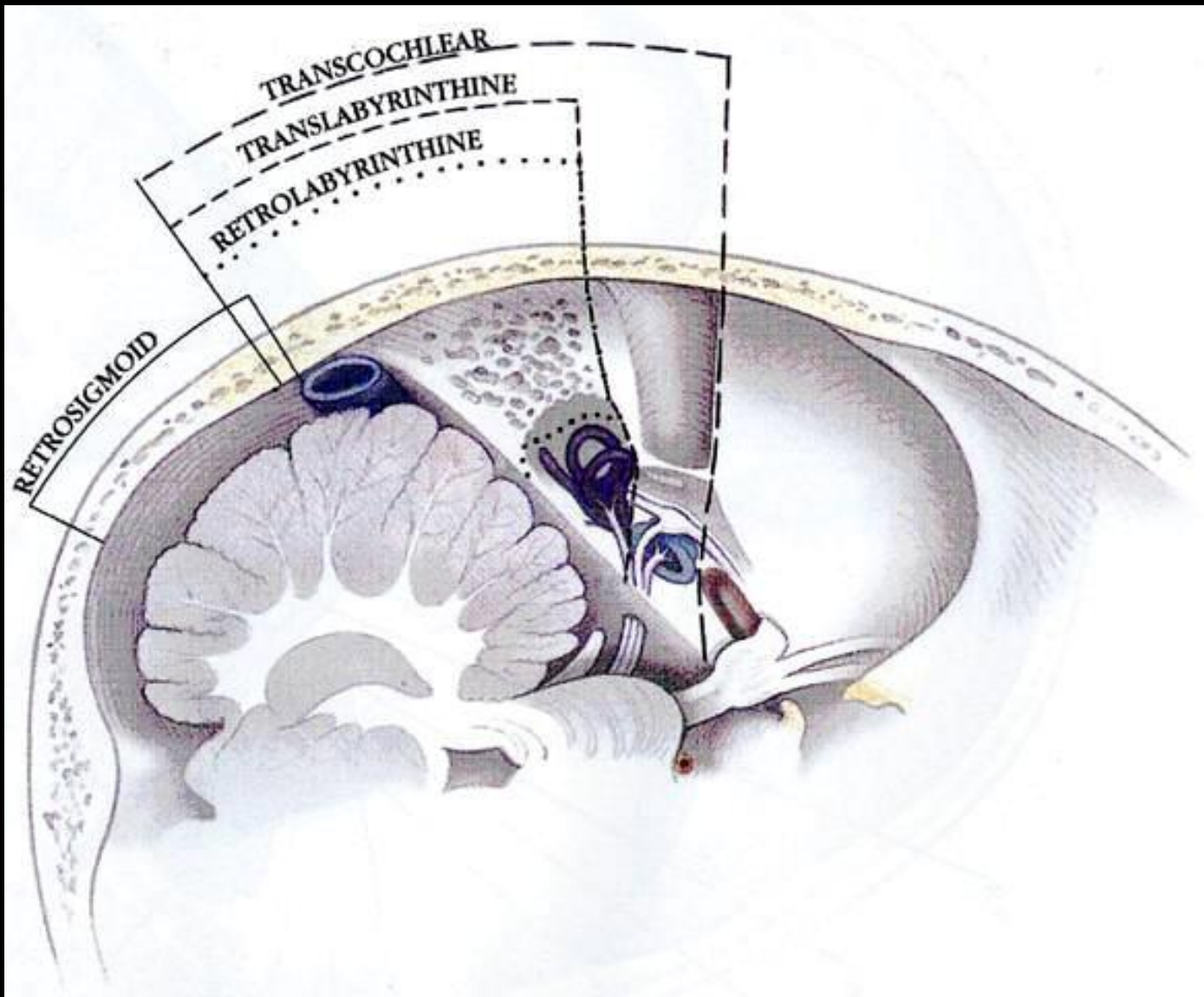


Behandling



Surgical approaches

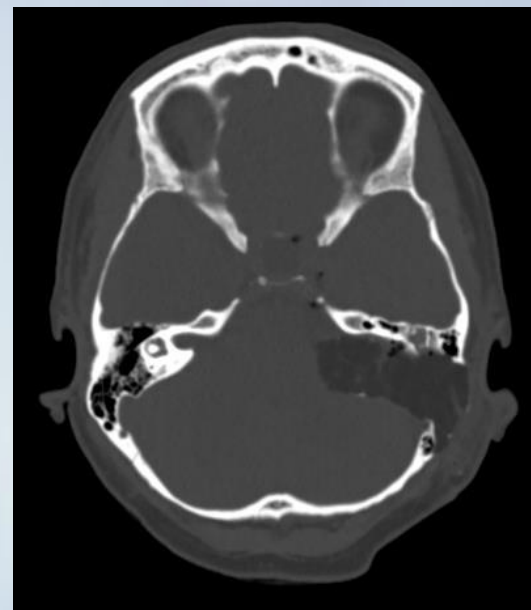
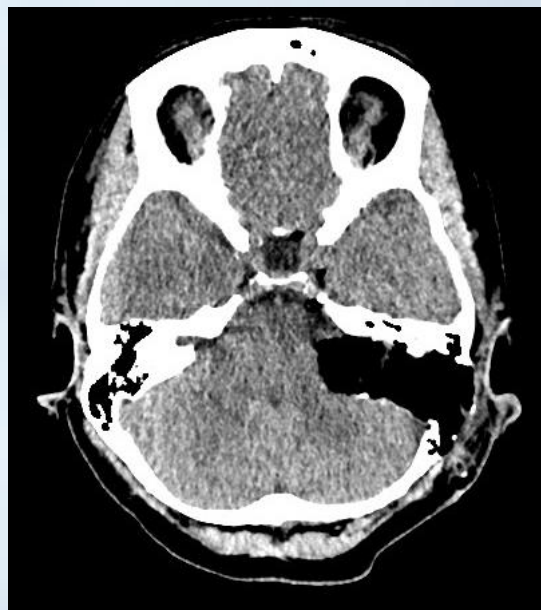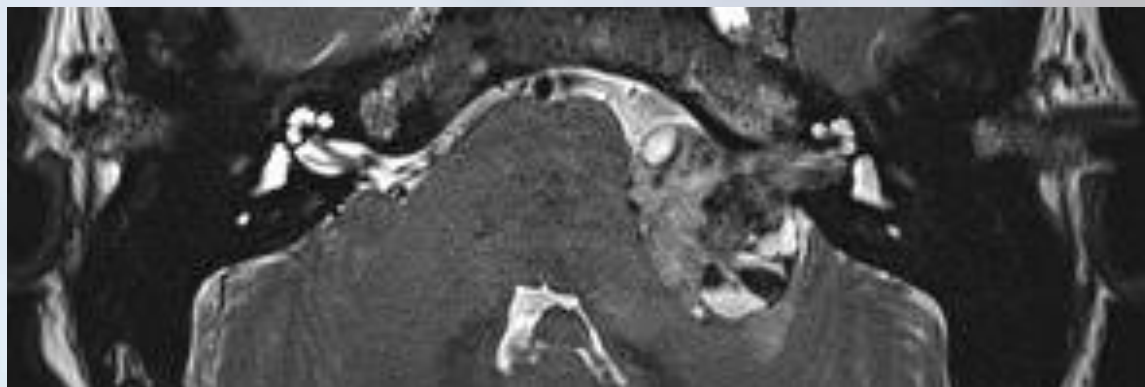


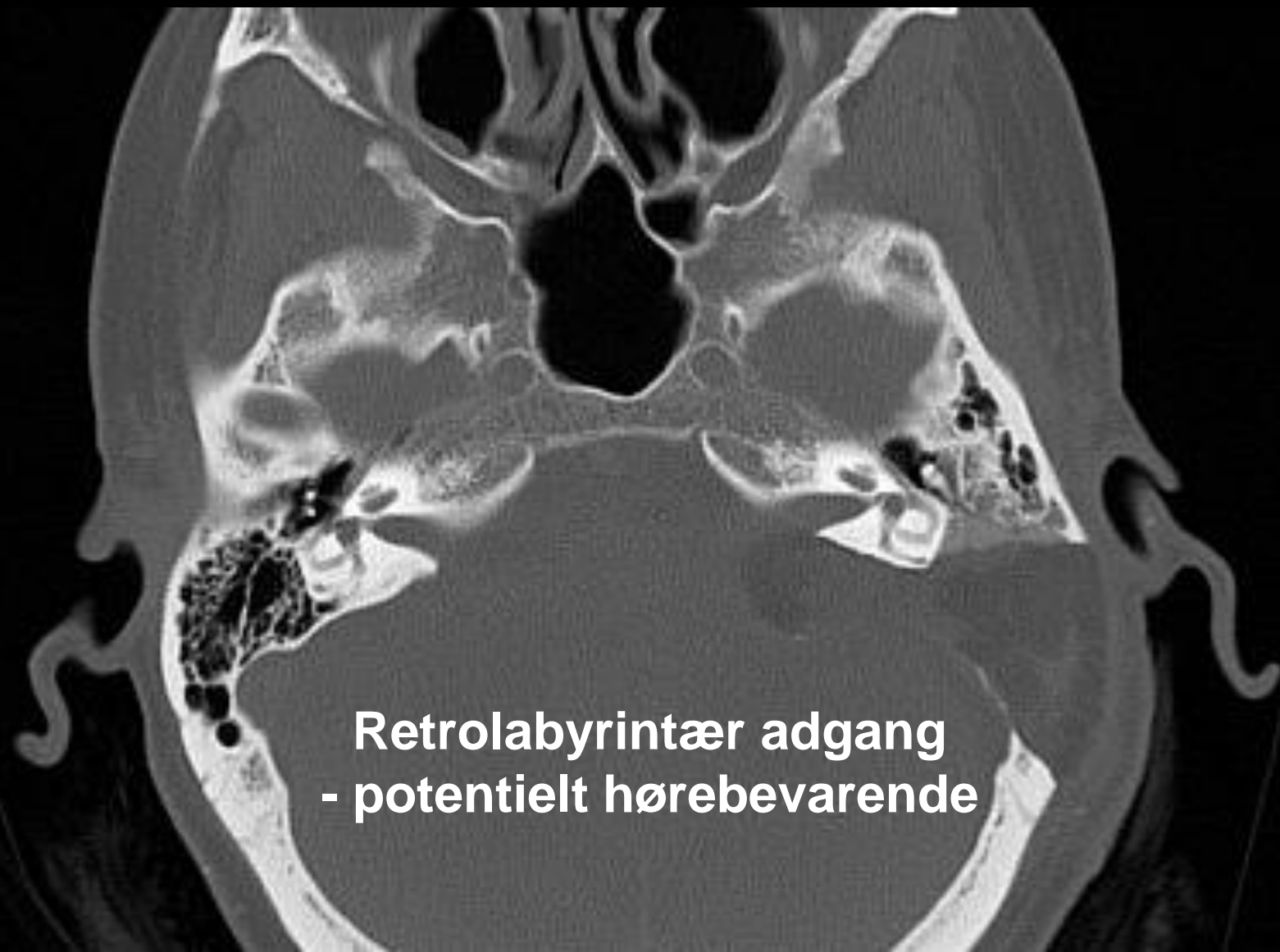




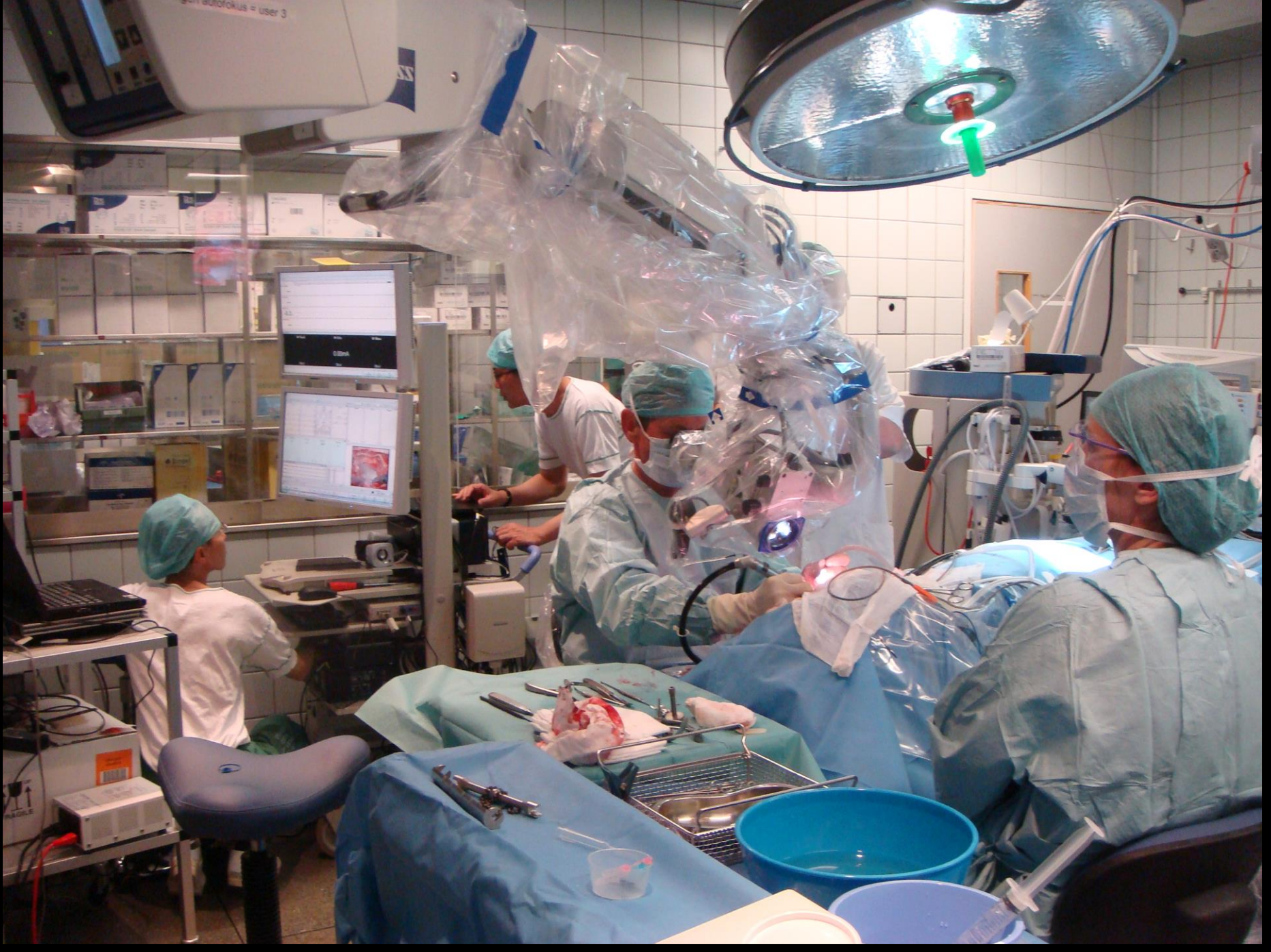Vestibularis schwannom

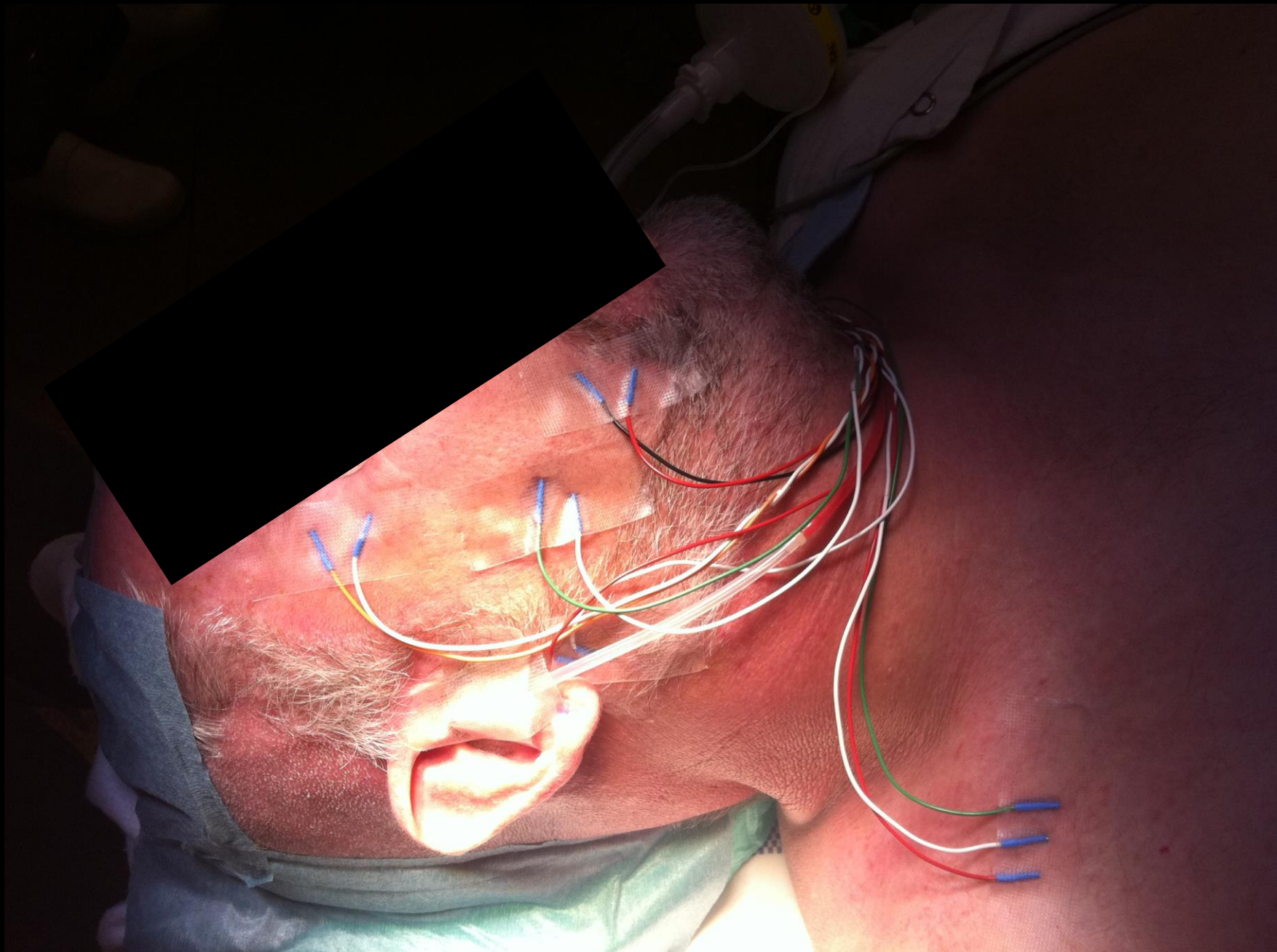Translabyrinthær adgang





**Retrolabyrinthær adgang
- potentielt hørebevarende**







Vestibularis schwannom

Komplikationer kirurgi

Høretab 25-90% (retrolab adgang)

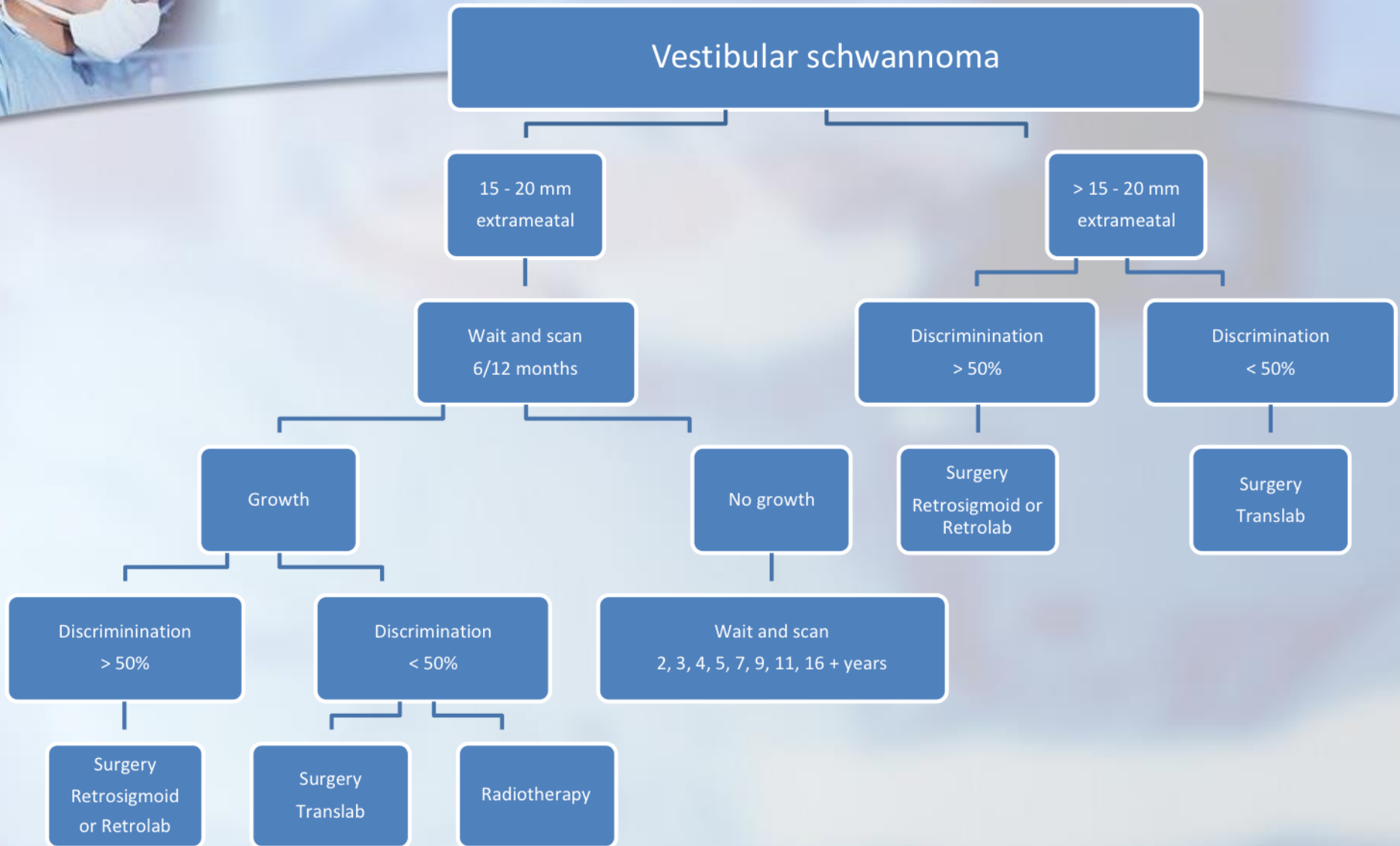
Facialisparese 5-90%

Rhino-liquorrhoe 5-10%

Andre: sinus sigmoideus trombose, meningitis, post-op hæmatom



Behandling





Tak for opmærksomhed!



Per Caye-Thomasen

Department of Oto-Rhino-Laryngology, Head & Neck Surgery



University of Copenhagen



Denmark